

The impact of hydrosurgical debridement on wounds containing bacterial biofilms

Nick Allan¹, Merle Olson¹, Dennis Nagel² and Robin Martin³

¹Innovotech Inc., Edmonton, Canada, ²Innovotech Animal Resource Centre, Crossfield, Canada, ³Smith & Nephew Medical Ltd, Hull, UK. Correspondence to: nick.allan@innovotech.ca or robin.martin@smith-nephew.com

Introduction

Bacterial biofilms are frequently present as micro-colonies within granulation tissue where they resist antibacterial therapies and cause delays to healing.^{1,2,3} We have assessed the effect of VERSAJET[®] tangential hydrosurgical debridement⁴⁻⁷ on wound biofilms using a polymicrobial porcine model⁸ to see how great a reduction in levels of embedded biofilm bacteria can be achieved.

Materials and Methods

Full thickness wounds¹⁶ were made on the flanks of 6 Yorkshire pigs (see Figure 1). Each wound was inoculated with a mixture of *Pseudomonas aeruginosa*, *Staphylococcus epidermidis* and *Fusobacterium necrophorum* as previously described.⁸ After 7 days all wounds were filled with a sloughy granulation tissue (see Figure 1). The VERSAJET handpiece uses a high pressure fluid jet parallel to the tissue surface to create a Venturi effect which draws soft tissues into the fluid path where they are cut and debris is evacuated⁴⁻⁷ (see Figure 2). Up to 2 wounds on each animal were subjected to a single episode of tangential hydrosurgical debridement (at power setting 7) to produce a smooth, clean granulation surface (see Figure 3). Up to 6 wounds were left untreated as controls. Biopsies (4 mm punch) were harvested for determination of bacterial counts, myeloperoxidase enzyme activity and histology before and after debridement. The remaining wounds were allowed to heal.

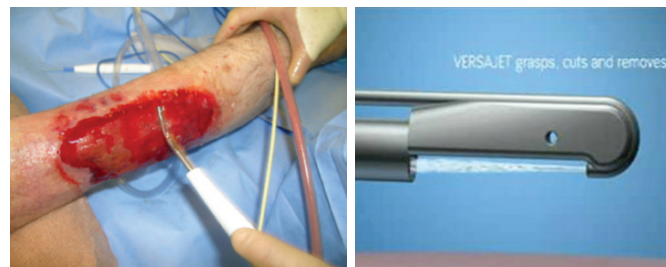


Figure 2: Operation of VERSAJET tangential hydrosurgery device⁴⁻⁷

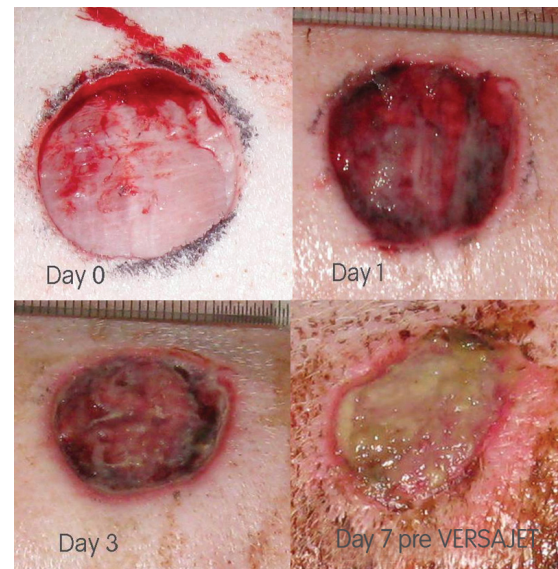


Figure 1: Development of polymicrobial biofilm containing granulation tissue over 7 days a porcine wound model.⁸

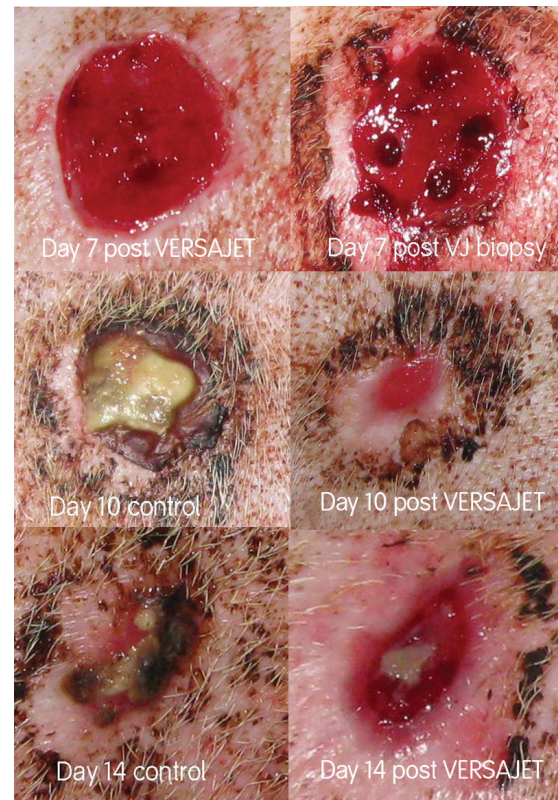


Figure 3: Changes in wound appearance with and without VERSAJET debridement on day 7. The upper left image shows the appearance of the wounds immediately after debridement.

Results

After 7 days biopsies from control wounds contained high levels of a mixture of all 3 input bacteria at close to 10^9 CFU (colony forming units) per g tissue (see Figure 5). Histology confirmed that embedded bacterial micro-colonies were present throughout the granulation tissue (see Figure 4). Following VERSAJET hydrosurgical debridement, the levels of embedded bacteria were compared statistically using non parametric tests. Bacteria were reduced from a median \log_{10} 8.4 (range 8.1-9.1) CFU g^{-1} tissue to a median of \log_{10} 5.5 (5.1-6.9) CFU g^{-1} tissue, a reduction of (\log_{10} 2.8) ($n=6$, $P= 0.031$). Figure 6 shows that VERSAJET hydrosurgical debridement also significantly reduced the levels of the inflammatory neutrophil marker myeloperoxidase. The differences were tested with non parametric tests and found to be statistically significant: median (control) 15.80 (range 11.7-20.0) to (VERSAJET) 4.00 (range 3.2-5.3) $ng\ mL^{-1}$ biopsy tissue extract ($n=6$, $P= 0.031$). Figure 4 shows a significant improvement in wound bed tissue quality.

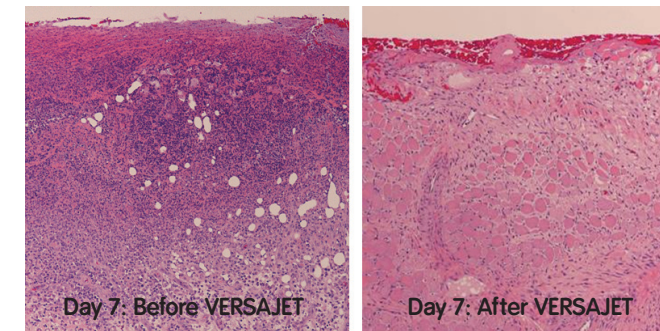


Figure 4: H&E stained biopsy tissue before and after VERSAJET debridement at day 7

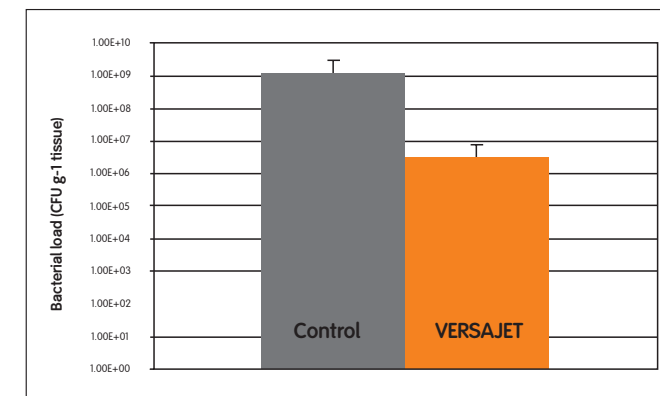


Figure 5: \log_{10} quantitative bacterial levels assessed on aerobic tryptic soy agar plates (CFU g^{-1}) from wounds before and after VERSAJET debridement at day 7 ($n=6$ mean \pm SD; $P= 0.031$). Similar results were obtained for anaerobic and selective MaConkey agar indicating all 3 input bacteria are present.

Discussion

It is becoming established that delayed healing wounds often contain bacteria in complex communities of polymicrobial biofilms embedded in granulation tissue.^{1,2,3} For this reason it is recognized that surgical debridement is an important component of strategies to achieve wound healing and closure.⁹ Although established in regular clinical practice, VERSAJET hydrosurgery⁴⁻⁷ has not yet been proven to be able to remove biofilm bacteria embedded in granulation tissue. In this study high levels of bacteria present as embedded micro colonies were reduced by close to 1000 fold by VERSAJET debridement of the biofilm infected granulation tissue. Inflammatory neutrophil markers were also reduced. Further reduction would have been possible by removal of greater depths of granulation tissue but the wounds were brought to a smooth clean surface, level with the surrounding tissue as is common in clinical practice. It can be concluded that VERSAJET is an effective tool to remove biofilm contaminated tissues.

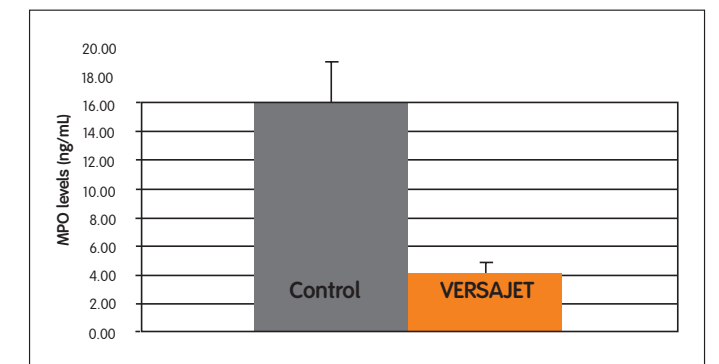


Figure 6: Levels of myeloperoxidase inflammatory marker ($ng\ mL^{-1}$ biopsy extract) in wounds before and after VERSAJET debridement at day 7 ($n=6$ mean \pm SD; $P= 0.031$)



The impact of hydrosurgical debridement on wounds containing bacterial biofilms

Nick Allan¹, Merle Olson¹, Dennis Nagel² and Robin Martin³

¹Innovotech Inc., Edmonton, Canada, ²Innovotech Animal Resource Centre, Crossfield, Canada, ³Smith & Nephew Medical Ltd, Hull, UK.

Correspondence to: nick.allan@innovotech.ca or robin.martin@smith-nephew.com

References

1. Bjarnsholt *et al.* (2008) Why chronic wounds will not heal: a novel hypothesis. *Wound Repair Regen.* 16(1):2-10.
2. Davis *et al.* (2008) Microscopic and physiologic evidence for biofilm-associated wound colonization in vivo. *Wound Repair Regen.* 16(1):23-9.
3. Percival *et al.* (2010) Biofilms and bacterial imbalances in chronic wounds: anti-Koch. *Int Wound J.* 7(3):169-75.
4. Vanwijck *et al.* (2010) Immediate skin grafting of sub-acute and chronic wounds debrided by hydrosurgery. *J Plast Reconstr Aesthet Surg.* 63(3):544-9.
5. Caputo *et al.* (2008) A prospective randomised controlled clinical trial comparing hydrosurgery debridement with conventional surgical debridement in lower extremity ulcers. *Int Wound J.* 5(2):288-94
6. Gurunluoglu R. (2007) Experiences with waterjet hydrosurgery system in wound debridement. *World J Emerg Surg.* 2;2:10
7. Mosti *et al.* (2005) The debridement of hard to heal leg ulcers by means of a new device based on Fluidjet technology. *Int Wound J.* 2(4):307-14.
8. Wright *et al.* (2002) Early healing events in a porcine model of contaminated wounds: effects of nanocrystalline silver on matrix metalloproteinases, cell apoptosis, and healing. *Wound Repair Regen.* 10(3):141-51.
9. Wolcott *et al.* (2009) Regular debridement is the main tool for maintaining a healthy wound bed in most chronic wounds. *J Wound Care.* 18(2):54-6.

Wound Management

Smith & Nephew Inc
970 Lake Carillon Drive
Suite 110
St. Petersburg, FL 33716
USA

www.smith-nephew.com/wound

™Trademark of Smith & Nephew
© Smith & Nephew February 2011

Customer Care Center
1 800-876-1261
T 727-392-1261
F 727-392-6914

First presented at 20th Meeting of the European Tissue Repair Society, Gent, Belgium, September 15–17, 2010.

Abstract published at: Allan N, Olson M, Nagel D Martin R (2010). The impact of VERSAJET hydrosurgical debridement on wounds containing bacterial biofilms. *Wound Rep Reg* 18: A88.