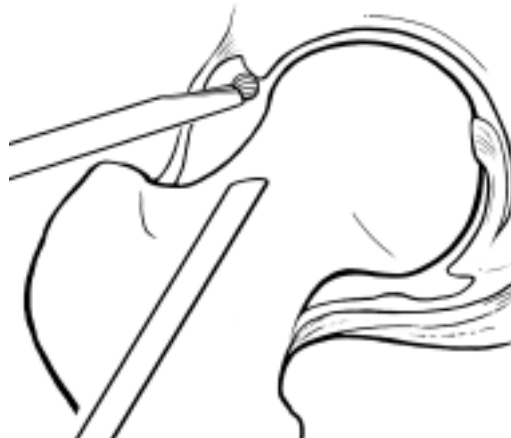

Arthroscopic treatment of femoroacetabular impingement

Thomas G. Sampson, MD



Thomas G. Sampson, MD

Director of Hip Arthroscopy, Post Street Surgery Center
Medical Director, Total Joint Center at St. Francis
Memorial Hospital, San Francisco
Associate Clinical Professor, University of California,
San Francisco

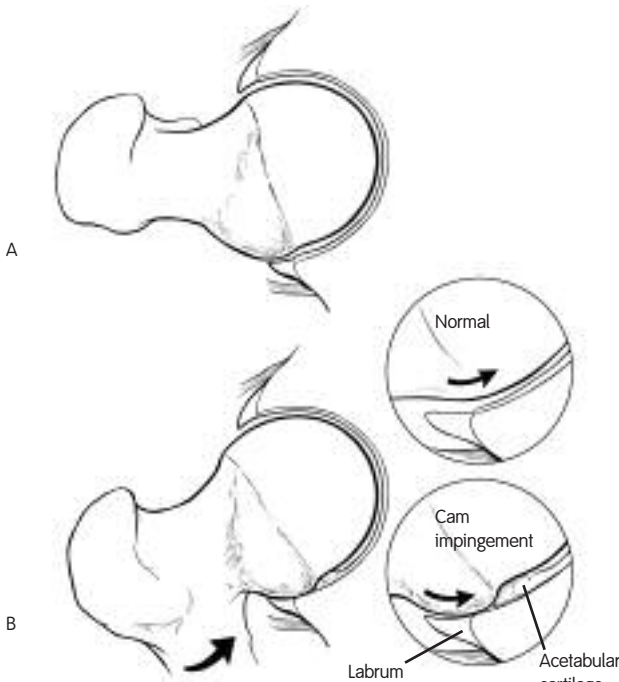


Figure 1

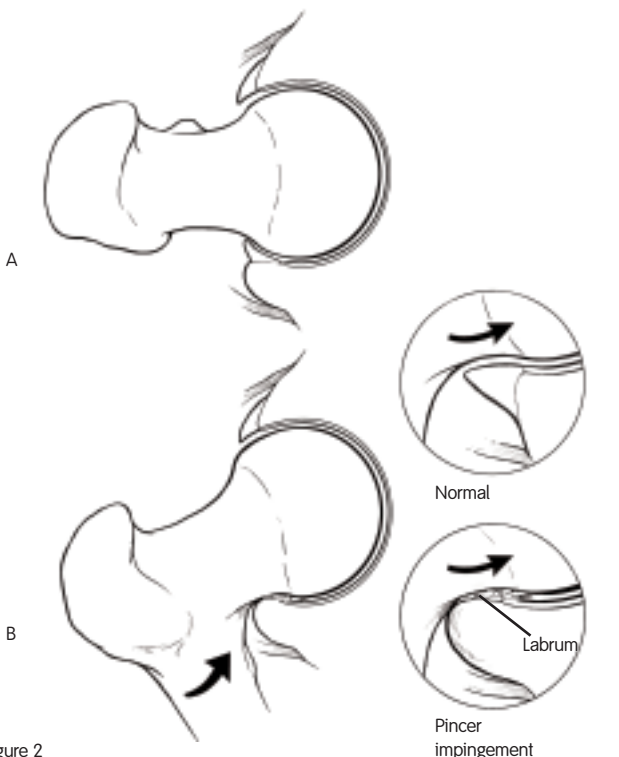


Figure 2

Arthroscopic treatment of femoroacetabular impingement

Introduction

Femoroacetabular impingement (FAI) syndrome is increasingly being recognized as a cause of osteoarthritis in the hip through deterioration of the labrum and articular surface. There are two types: Pincer (acetabular) impingement and Cam (femoral) impingement, which can occur separately or coexist.

“Cam” impingement occurs due to an alteration of the femoral head-neck junction (Figure 1). The impingement is caused by entry of an abnormal femoral head with increasing radius into the acetabulum during forceful motion, especially flexion.

There is increasing evidence that this decreased offset either overloads the articular cartilage causing chondral injury or delamination defects of the anterior acetabulum with separation and tearing of the adjacent labrum.

“Pincer” impingement occurs due to an acetabular abnormality. Impingement is caused by linear contact between the acetabular rim and the femoral head-neck junction (Figure 2).

Femoroacetabular impingement has been successfully treated through open surgical dislocation. Hip arthroscopy is also quickly becoming a useful tool for addressing FAI.

Patient positioning and arthroscopic evaluation

Position the patient in either the lateral or supine position.

Arthroscopy for cam impingement occurs in the peripheral compartment of the hip without traction. Thus, free draping is used to provide both a wide range of motion and the ability to remove traction after the initial arthroscopic evaluation without contaminating the surgical field.

After the leg is in traction, use fluoroscopy to examine the hip, looking for the minimal offset or flattening of the femoral head-neck junction or a lateral bony excrescence. It may appear as a pistol grip deformity. This is best seen with the hip in

maximum external rotation, which rotates the anterior aspect of the femoral head into the field of view.

Establish the three standard hip arthroscopy portals (anterolateral, posterolateral and anterior).

Perform a standard arthroscopic evaluation of the hip. See the Smith & Nephew Diagnostic Hip Arthroscopy Animated CD-ROM (REF 10600027) for more information on diagnostic hip arthroscopy. Typical findings in a patient with FAI are fraying or tearing of the labrum anteriorly and laterally. There may be anterior acetabular articular cartilage damage from grade one to four and occasionally extending from mid-lateral to posterior. Probing can be used to uncover delamination defects hiding under normal appearing cartilage.

Debride and smooth the labrum and cartilage with a shaver or radiofrequency device. Repair the labrum as needed. Resect any acetabular rim osteophytes behind the intact labrum. Abrade or microfracture exposed bone. Remove any loose bodies.

Arthroscopic pincer impingement treatment

The bony acetabular lesion of pincer impingement is addressed from the central compartment with the joint distracted. There are three arthroscopic signs: 1) damage to the anterior labrum with a variable amount of associated articular pathology; 2) the overhanging lip of bone makes positioning of the anterior portal difficult despite adequate joint distraction; and 3) the pincer impingement becomes evident as the damaged labrum is selectively debrided, revealing a bony prominence overhanging the labrum instead of the normal capsular reflection (Figure 3).

Debridement of the damaged labrum exposes the impingement lesion, which is then excised with a burr ("acetabuloplasty"). Viewing from the anterolateral portal, excision begins with the burr brought in anteriorly, creating a flush resection with the anterior column of the acetabulum (Figure 4).

With the arthroscope in the anterior portal, excision is completed with the burr in the anterolateral portal (Figure 5). The margin of bony excision is delineated by transition to healthy labrum laterally and inferomedial.

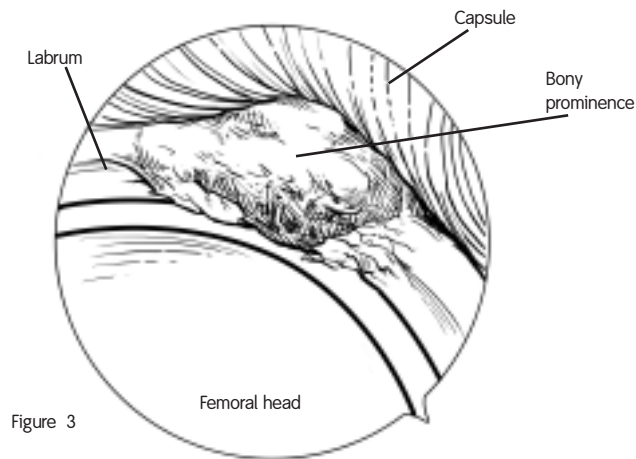


Figure 3

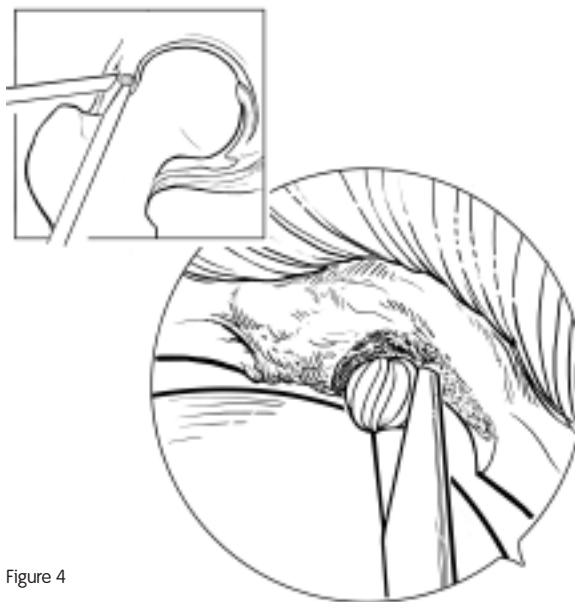


Figure 4

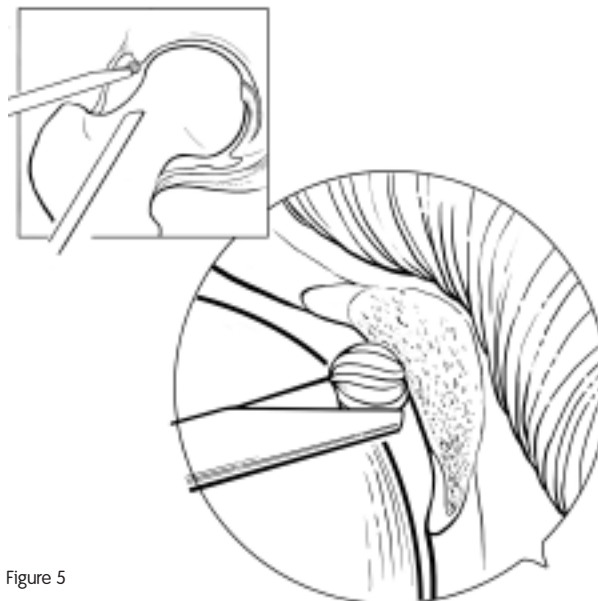


Figure 5

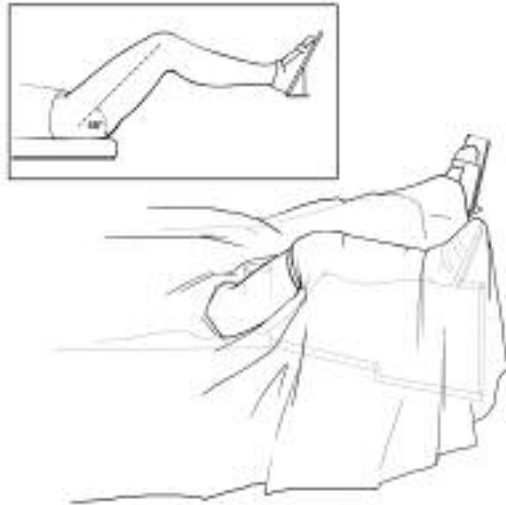

Figure 6

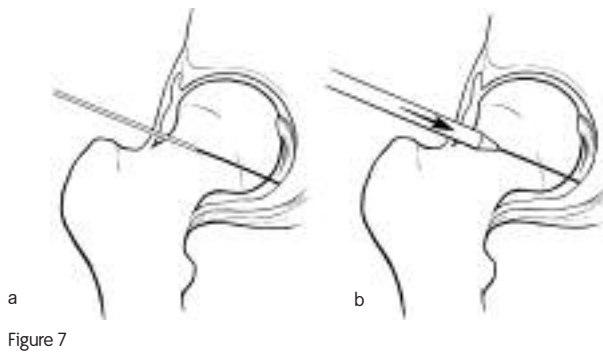


Figure 7

Arthroscopic cam impingement treatment

Radiographic findings of cam impingement may be common, even among asymptomatic hips. Thus, the arthroscopic finding of articular delamination with peel back from its junction with labrum, characteristic of cam impingement, is an important finding in the decision to proceed with recontouring of the femoral head (“femoroasty”). Also, two-dimensional radiographs are often a poor reflection of the three-dimensional nature of cam impingement. For cases indicated for surgery, a CT scan with three-dimensional reconstructions is very helpful in planning the extent of femoroasty. Careful mapping of the lesion to be excised is essential to assure an adequate bony resection.

After completing arthroscopy of the central compartment, the instruments are removed and the traction is released. In the supine position, flex the hip to 35–40° (Figure 6). Flexion relaxes the anterior iliofemoral ligament and leads to a significant increase in the joint space of the anterior and medial head and neck area. In the lateral position, the hip may also be flexed to relax the capsule. However, it may be technically easier to do a capsulectomy. Note: Excessive flexion would move part of the bony lesion to be excised underneath the acetabulum and out of view from the peripheral compartment.

From the anterolateral portal, use an arthroscopic needle to penetrate the capsule of the anterior neck of the femur (Figure 7a). Use fluoroscopy to confirm positioning. Use the trocar to separate the muscle from the capsule (Figure 7b).

A distal lateral accessory portal may be needed in the supine position. Under direct visualization, place the accessory portal approximately 5 cm distal to the anterolateral portal. The portal typically enters the capsule at the level of the zona orbicularis and allows for direct access to the anterior neck (Figure 8).

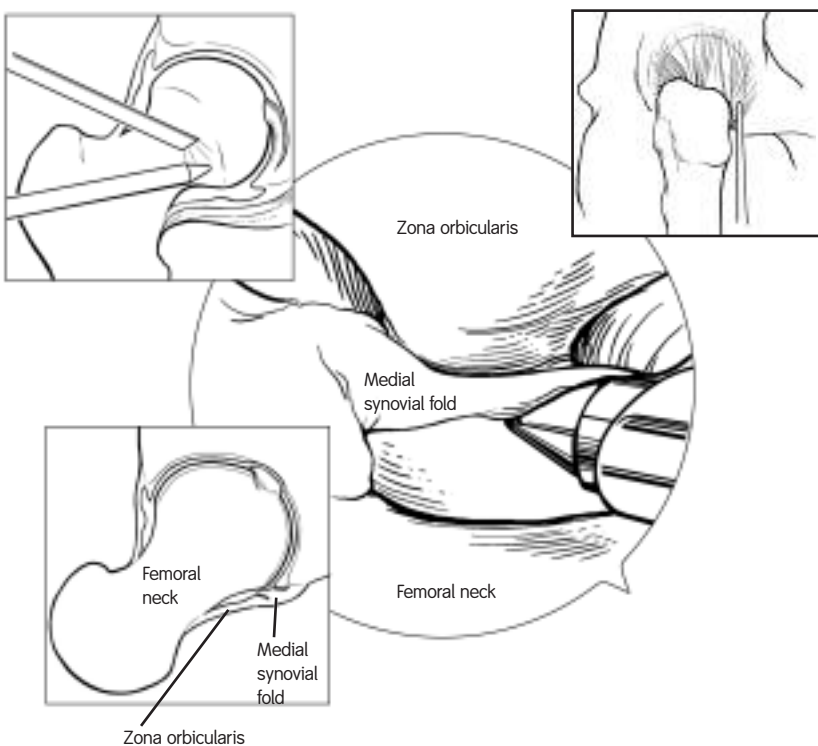


Figure 8

If needed, perform an anterior capsulectomy using a radiofrequency device, banana blade knife, and/or a shaver blade. Cut the capsule as a “T” or “H” until viewing the bump and medial and lateral neck (Figure 9).

During this process the foot is maintained in maximum external rotation to position important retinacular vessels, **particularly the lateral epiphyseal branch of the medial circumflex femoral artery**, posterior and away from the capsulectomy (Figure 10).

Warning: damage to the medial femoral vessels may lead to avascular necrosis of the femoral head.

After exposure of the bony bump, a cleft or tidemark at the osseous cartilaginous junction at the femoral head neck junction and the base of the neck may be seen. The bony bump, once exposed, has an appearance of areas of erosion mixed with erythematous grayish irregular surfaces. It does not resemble normal bone, cartilage or periosteum.

It is essential to first visualize the entirety of the lesion to be excised and debride overlying soft tissue. Fibrocartilage may cover a portion of the bone making it difficult to distinguish from the normal femoral head. As a result, preoperative planning and good intraoperative visualization are critical.

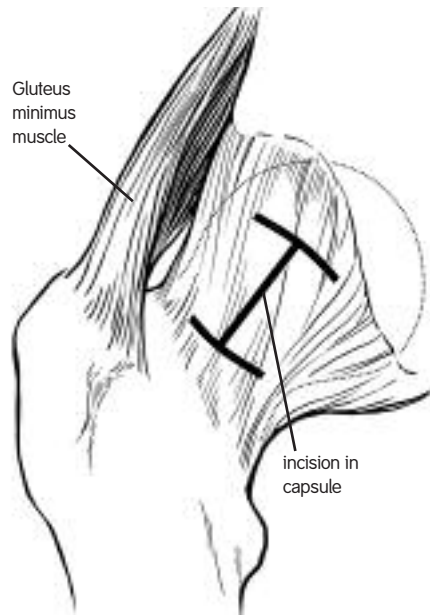


Figure 9

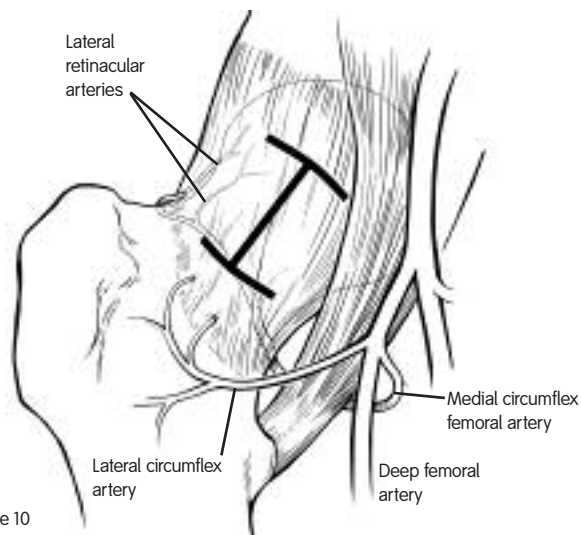


Figure 10

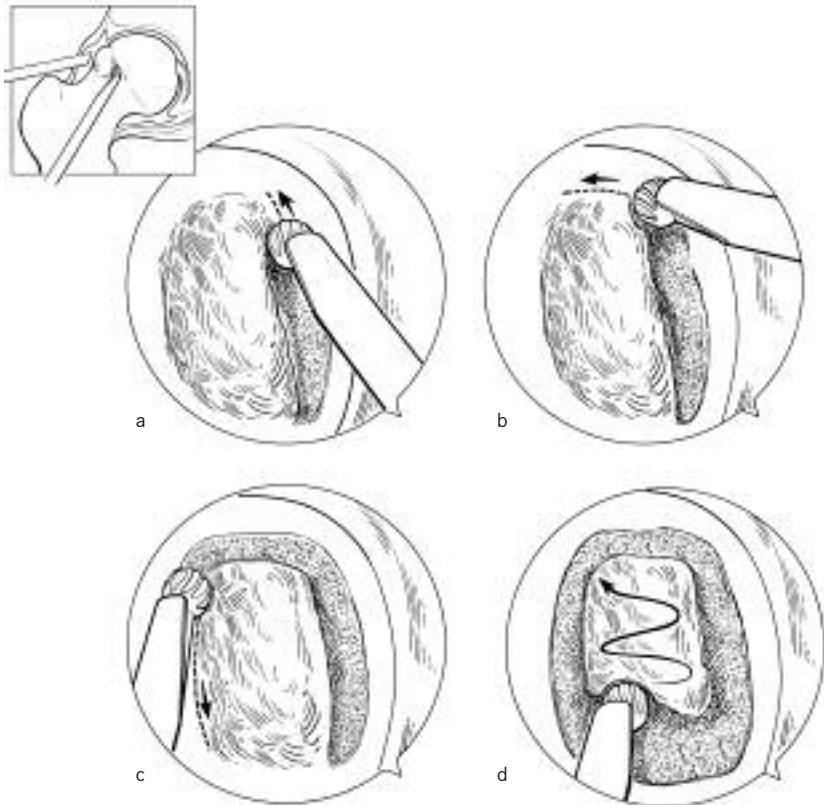


Figure 10

Use a 4.0 or 5.5 mm, extra length, partially hooded, round burr to perform the resection osteoplasty. Begin by outlining the area of resection first (Figures 10 a–c) and then contour between the outlines (Figure 10d). Move the scope and burr between portals to provide a 3-D view. It is critical to avoid “notching” at the distal limit of resection, which would create a stress riser and increase the risk of femoral neck fracture. Laterally, the resection should not extend posterior to the mid-coronal line of the femoral head. The more posterior resection should remain proximal, closest to the head-neck junction. This minimizes the risk of injury to the lateral retinacular vessels. There are twelve to fourteen retinacular vessels. If, during posterior debridement, a cortical perforation for one of these vessels is encountered, this is the point to stop.

Throughout the procedure, take several x-rays with the fluoroscope to ensure that adequate contouring is done and enough bone is resected. The convex shape of the excrescence is sculpted to a concave shape circumventrally from anterolateral to anteromedial (Figure 11).

Detach the leg from the traction device and put it through a range of motion while under direct view from the arthroscope to document clearance at the head-neck junction and the acetabular rim.

Following completion of the resection, meticulous debridement of all morselized bone is imperative to minimize any risk of heterotopic ossification.

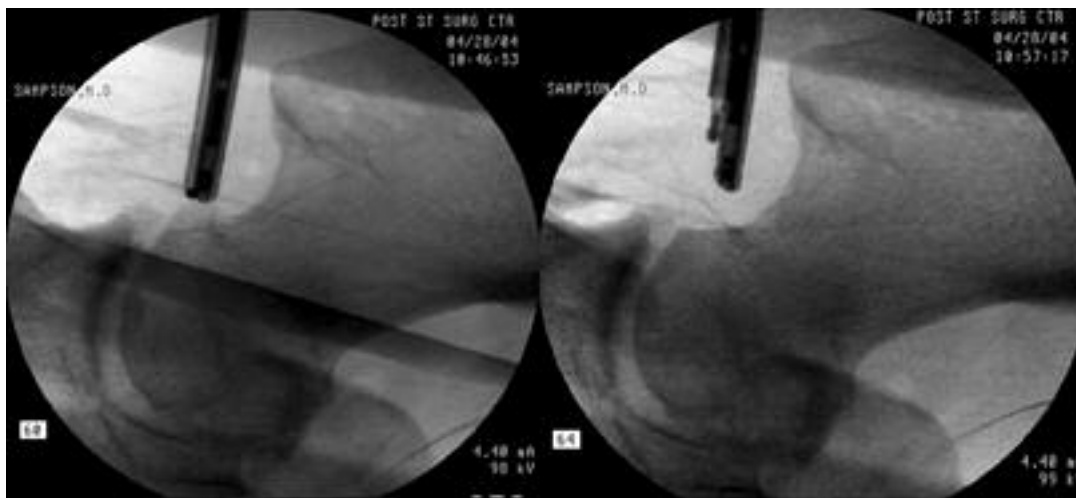


Figure 11

Postoperative care

Place the patient on two crutches for protected weight-bearing and fall prevention.

Patient is allowed to shower the next day and come off crutches from 2–4 weeks when they feel they are stable.

Patient may begin a range of motion exercise such as the use of a stationary bicycle or swimming. Patient should not engage in any sporting activities or excessive activities for one month.

At one month, the activity level is increased and PT is used if the patient's range of motion is poor. By three months all restrictions are removed.

Additional Instruction

Prior to performing this technique, consult the Instructions for Use provided with individual components — including indications, contraindications, warnings, cautions, and instructions.

Courtesy of Smith & Nephew, Inc.,
Endoscopy Division

Caution: U.S. Federal law restricts this device to sale by or on the order of a physician.