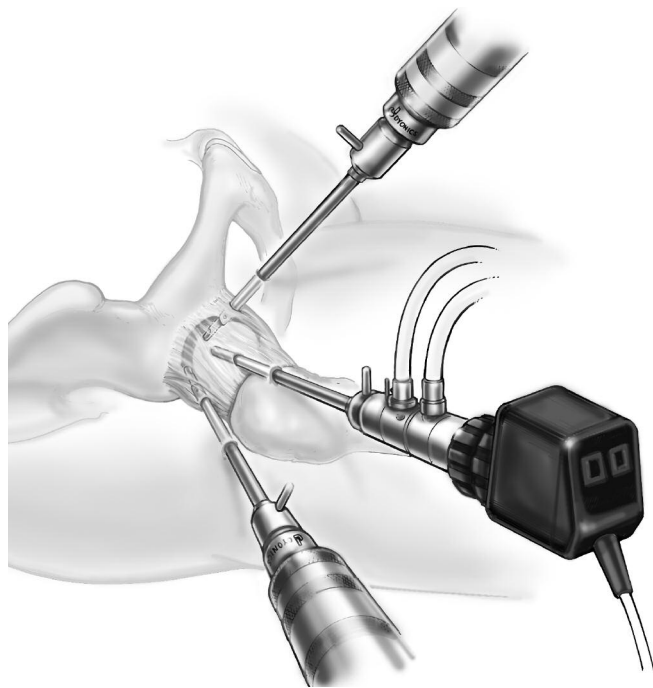


# Hip Arthroscopy Principles and Application

J.W. Thomas Byrd, M.D.



*As described by:*

J.W. Thomas Byrd, M.D.  
Southern Sports Medicine and Orthopaedic Center  
Nashville, TN

## Introduction

Arthroscopic techniques have found wide applicability in both large and small joints of the body. In the hip, however, the application of these techniques brings to light a number of unique considerations. The hip is encased in a dense soft tissue envelope that makes the introduction of arthroscopic instruments challenging. Further, the constrained ball and socket's bony architecture limits both access and maneuverability of instrumentation within the joint. Finally, the strong, relatively non-compliant capsule is a factor in achieving adequate distraction of the joint. Despite these challenges, arthroscopic surgery of the hip is becoming an increasingly well-recognized clinical procedure. With well-founded basic principles, the techniques of hip arthroscopy are evolving and the indications continue to expand. Hip arthroscopy is proving to be an invaluable tool in defining certain intraarticular lesions. Imaging techniques such as MRI — which are often important in discerning arthroscopically amenable lesions in joints such as the shoulder and knee — are currently less reliable in the hip. Observations made during hip arthroscopy can enhance our ability to more accurately interpret diagnostic images and to correlate clinical findings with pathology.

# Hip Arthroscopy Principles and Application

## Patient Selection

Indications for hip arthroscopy include:

- Loose bodies
- Labral tears
- Degenerative disease
- Chondral injuries
- Synovial disease
- Joint sepsis
- Avascular necrosis
- S/P total hip arthroplasty
- Ruptured ligamentum teres
- Unresolved hip pain

Removal of loose bodies represents the clearest indication for hip arthroscopy. The diagnosis is usually evident with currently available imaging techniques including arthrography or arthro-CT scan. Once diagnosed, the importance of loose body removal has been well documented. Arthrotomy for debridement carries greater associated morbidity than hip arthroscopy.

Labral tears are more elusive to diagnose than loose bodies. Neither MRI nor various arthrography techniques are fully reliable in defining labral lesions. Were it not for the option of arthroscopic intervention, many of these patients would be resigned to living within the constraints of their symptoms. However, with arthroscopy, a definite diagnosis can be made and effective treatment instituted. Successful arthroscopic debridement of symptomatic labral tears can produce very gratifying results.

Arthroscopic debridement has a limited role in the management of select patients with degenerative disease. It is a palliative and temporizing procedure that may potentially delay the subsequent need for total hip arthroplasty.

Similar to labral lesions, the diagnosis of isolated chondral injuries may be elusive. However, when recognized, these injuries represent an excellent indication for arthroscopic management. Arthroscopy has also found a role in select synovial disease and joint sepsis.

Arthroscopic debridement in association with avascular necrosis of the femoral head has a very limited place. Similarly, arthroscopy has occasionally been reported for removal of debris associated with total hip arthroplasty. Rupture of the ligamentum teres has been discerned arthroscopically and arthroscopy has also been reported for select cases of unresolved hip pain.

## *Contraindications*

Hip arthroscopy is contraindicated in the presence of ankylosis or advanced arthrofibrosis.

Soft tissue compromise, whether from disease, trauma or previous surgery, may contraindicate the passage of instruments into the hip joint. Similarly, bony compromise, either of the joint architecture or potential stress risers, regardless of the cause, may contraindicate application of the distraction forces necessary for hip arthroscopy.

For hip arthroscopy, extra length instruments are usually necessary, even for moderate sized patients. Consequently, severe obesity may be a relative contraindication to arthroscopic intervention.

Advanced disease states with destruction of the hip joint also contraindicate arthroscopy as there can be no reasonable expectation of symptomatic improvement.

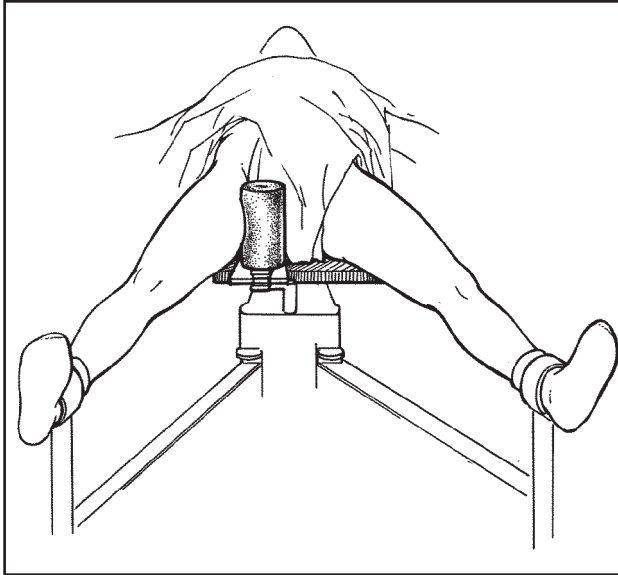


Figure 1. Supine position for hip arthroscopy requires a peroneal post lateralized to the operative side. The operative hip is placed in extension, approximately 25° abduction and neutral rotation.

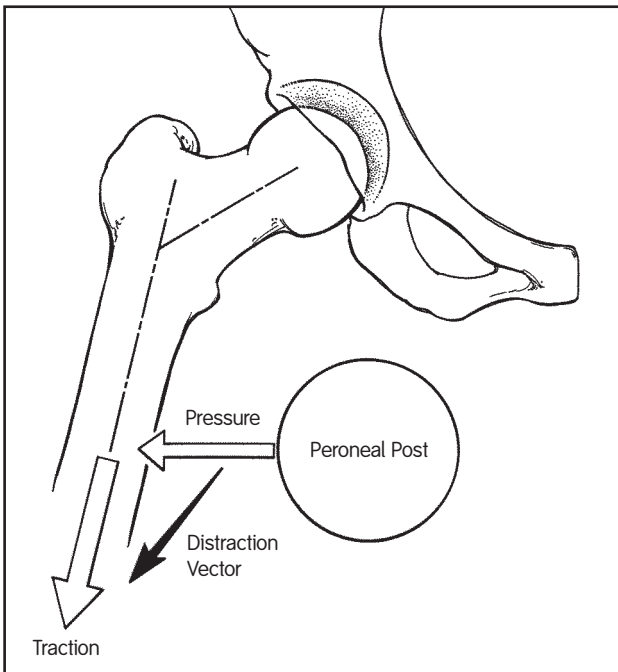


Figure 2. Optimal vector for distraction is oblique relative to the axis of the body and more closely coincides with the axis of the femoral neck than the femoral shaft. This oblique vector is partially created by hip abduction and partially accentuated by the small transverse component achieved by lateralizing the peroneal post.

## Operative Technique

Hip arthroscopy is performed as an outpatient procedure, and usually under general anesthesia. Epidural anesthesia is an appropriate alternative but requires an adequate motor block to ensure muscle relaxation.

### Patient Positioning

Hip arthroscopy can be performed with the patient in either of the following positions:

- Supine
- Lateral Decubitus

For the first option, the patient is positioned supine on a modified fracture table. An oversized, formed urethane peroneal post is used and lateralized to the operative side (Figure 1). Lateralizing the peroneal post adds a slight transverse component to the direction of the traction vector (Figure 2).

The operative hip is abducted approximately 25° and positioned in extension. Although slight flexion might relax the capsule and facilitate distraction, it also draws the sciatic nerve closer to the joint making it more vulnerable to injury. Thus, flexion of the hip joint during arthroscopy is avoided.

It is important that the operative hip be in neutral rotation during portal placement. However, freedom of rotation of the foot plate during arthroscopy should be assured to facilitate visualization of the femoral head.

The non-operative hip is abducted as necessary to accommodate placement of the draped C-arm between the legs. The contralateral foot is anchored with slight traction in order to keep the pelvis from shifting during distraction of the operative hip.

Traction is then applied to the operative extremity to confirm the ability to distract the joint. Adequate distraction typically requires 25 to 50 pounds of traction. More force may be necessary for an exceptionally tight hip but should only be applied with some caution. Distraction of the hip joint is confirmed by fluoroscopic examination.

If joint distraction is not readily achieved when initial traction is applied, immediate application of further traction should be avoided. Rather, a delay of a few minutes should be instituted to permit the capsule to accommodate to the tensile forces. This often results in relaxation of the capsule and adequate distraction without the need for further traction.

During fluoroscopic evaluation of hip distraction, a vacuum phenomenon in the joint will be apparent. This is caused by the negative intracapsular pressure created by joint distraction. The vacuum will be released when the joint is distended with fluid at the time of surgery. Although release of this vacuum may facilitate distraction, the effect is variable and should not be depended upon to overcome inadequate traction.

Once the ability to distract the hip joint has been confirmed, the traction is released. The hip is then prepped and draped. Traction is then immediately reapplied prior to the beginning of arthroscopy.

The surgeon, assistant and scrub nurse are positioned on the operative side of the patient (Figure 3). The monitor and arthroscopy cart are positioned on the contralateral side. The video-articulated arthroscopes and power shaver are placed on the sterile Mayo stand attached to the arthroscopy cart.

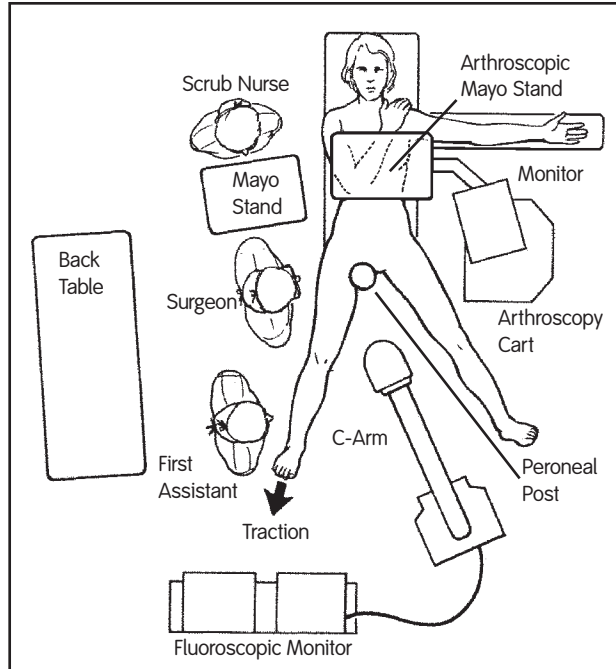


Figure 3. Layout of OR for hip arthroscopy.

To perform hip arthroscopy with the patient in the lateral decubitus position, a custom distractor is attached to a standard operating table. This distractor allows intraoperative range of motion of the hip while maintaining distraction. Although accommodation must be made for the change in joint orientation when hip arthroscopy is performed with the patient in this position, no change in arthroscopic technique is required.

### Equipment

Both 30° and 70° video-articulated arthroscopes are routinely used during hip arthroscopy. Interchanging the two arthroscopes allows excellent visualization despite the limited maneuverability caused by the bony architecture of the hip and its dense soft tissue envelope. The 70° scope will often enhance visualization of worrisome areas and, perhaps more importantly, it will occasionally allow the surgeon to identify lesions that might be missed with the 30° scope.

A fluid management system is essential for optimizing visualization during hip arthroscopy. Use of a high flow system allows adequate flow without excessive pressure thereby reducing extravasation of fluid from the joint.

Extra length cannulas are essential to accommodate the dense soft tissue envelope that surrounds the hip joint. A shortened bridge allows use of these cannulas with a standard arthroscope (Figure 4).

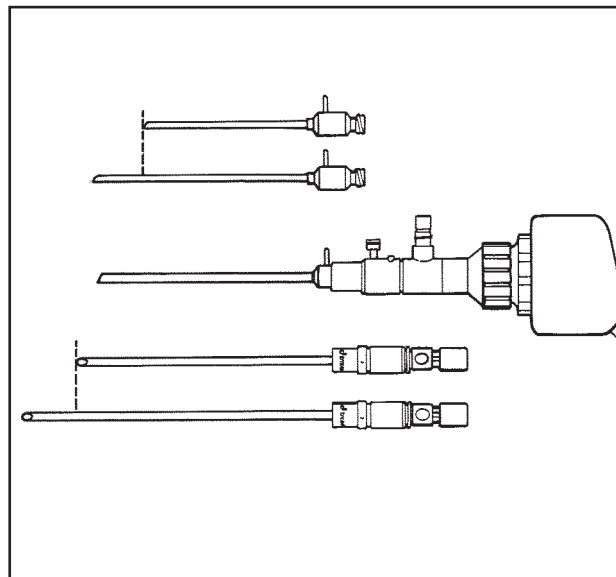


Figure 4. Extra length cannulas and short bridge facilitate hip arthroscopy.

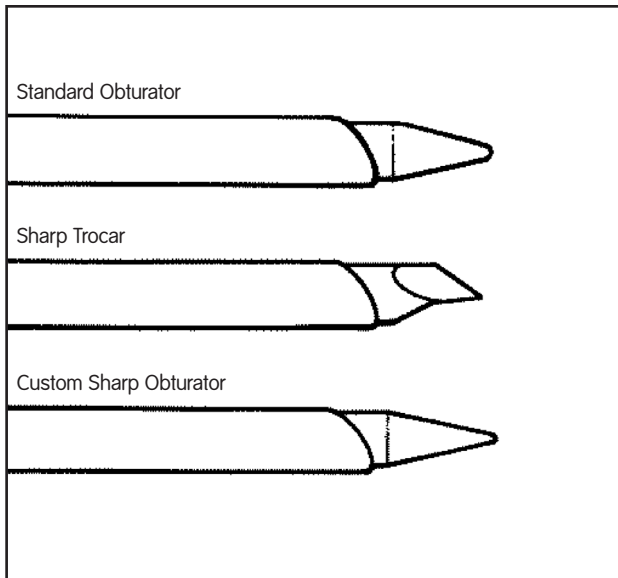


Figure 5. Obturators and Trocar.

4.5 mm, 5.0 mm and 5.5 mm extra length cannulas may be used during hip arthroscopy. A 4.5 mm cannula allows interchangeability of the arthroscope, instrumentation and the inflow. When the inflow is attached to the arthroscope bridge, a 5.0 mm cannula provides the best flow hydrodynamics. A 5.5 mm cannula is also available for extra length, large diameter shaver blades.

Special cannulated obturators can be advanced over a switching wire placed through the 17 gauge needle used in pre-positioning. Also, for freehand placement, a custom sharp obturator—rather than a trocar—allows for ease in penetrating the hip capsule with less risk of inadvertent articular damage (Figure 5).

Extra length curved shaver blades are useful for operative arthroscopy around the convex surface of the femoral head. Extra length flexible cannulas accommodate passage of the curved blades (Figure 6).

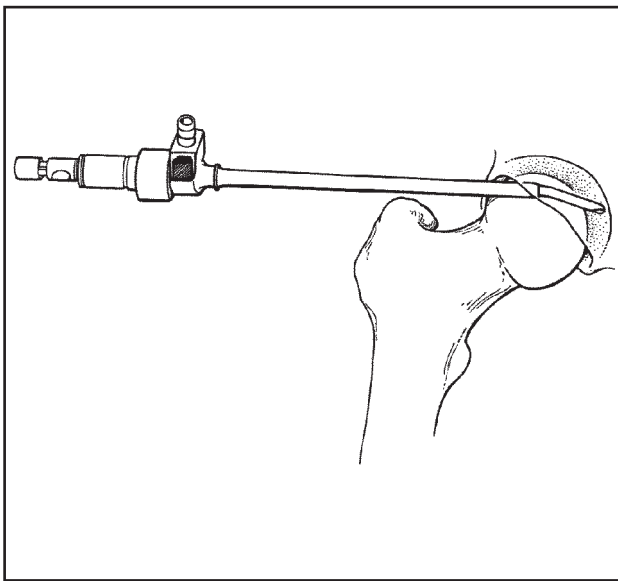


Figure 6. Extra length flexible cannula and extra length curved shaver blade facilitate operative arthroscopy around the femoral head.

Hip arthroscopy also requires arthroscopic hand instruments specifically designed for use in the hip joint. Importantly, although hand instruments commonly used in laparoscopic procedures may have the required extra length, they are fragile and may easily break if used in the hip. Consequently, endoscopic hand instruments are contraindicated for use during hip arthroscopy.

### Portal Location

Three standard portals are utilized for hip arthroscopy (Figure 7):

- Anterior
- Anterolateral
- Posterolateral

The site of the anterior portal coincides with the intersection of a sagittal line drawn distally from the anterior superior iliac spine and a transverse line across the superior margin of the greater trochanter. The direction of this portal courses approximately 45° cephalad and 30° towards the midline. The anterolateral and posterolateral portals are positioned directly over the superior aspect of the trochanter at its anterior and posterior borders.

### Anterior Portal\*

The pathway of the anterior portal penetrates the muscle belly of the sartorius and the rectus femoris before entering the anterior capsule (Figure 8). Neurovascular structures of concern during portal placement include the lateral femoral cutaneous nerve, the femoral nerve and the ascending branch of the lateral circumflex femoral artery.

At the level of the anterior portal, the lateral femoral cutaneous nerve typically divides into three or more branches. Consequently, the portal usually passes within several millimeters of one of these branches. Because of the multiple branches, the nerve is not easily avoided by altering the portal position. Rather, it is protected by utilizing meticulous technique in portal placement. Specifically, the nerve is most vulnerable to a deeply placed skin incision which lacerates one of the branches. Therefore, the initial stab wound should be made carefully through the skin only.

Passing from the skin to the capsule, the anterior portal runs almost tangential to the axis of the femoral nerve. The average minimum distance from the portal to the nerve is 3.2 cm.

Although variable in its relationship, the ascending branch of the lateral circumflex femoral artery is usually approximately 3.7 cm inferior to the anterior portal.

\* Anatomic references are based on cadaver studies and are averages only. Significant variances may exist. The surgeon must be fully familiar with the anatomy and landmarks of the region when performing hip arthroscopy.

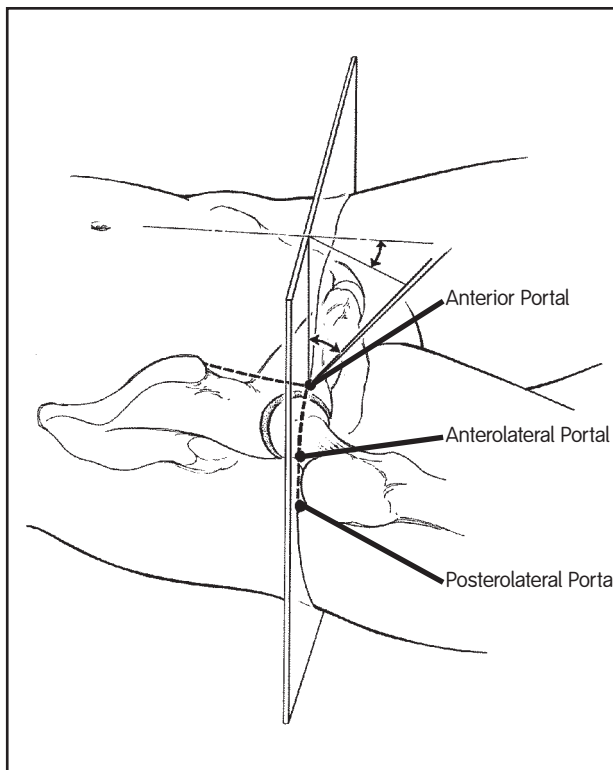


Figure 7. Anatomical landmarks guide portal positioning.

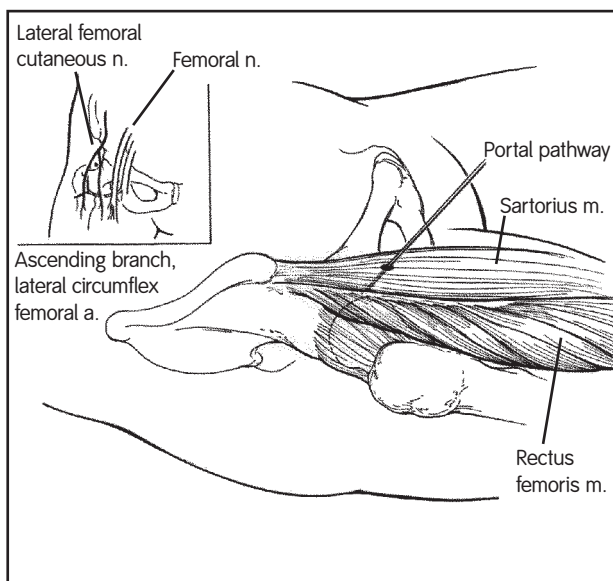


Figure 8. Anterior Portal Pathway/Relationship to Lateral Femoral Cutaneous Nerve, Femoral Nerve and Lateral Circumflex Femoral Artery

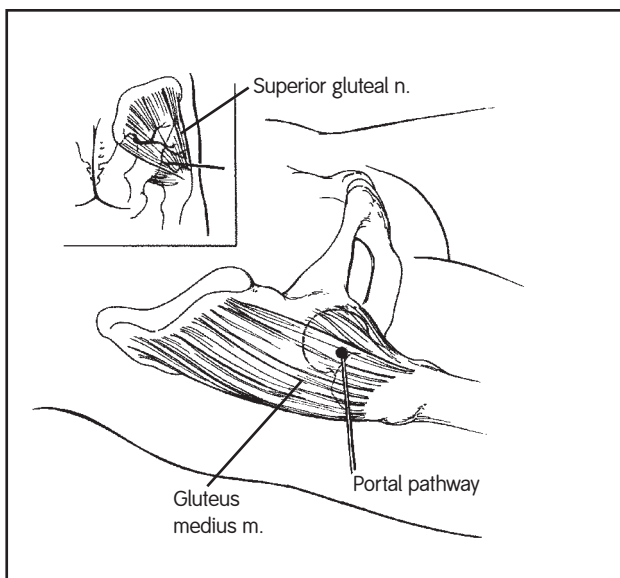


Figure 9. Anterolateral Portal Pathway/Relationship to Superior Gluteal Nerve

### *Anterolateral Portal\**

The anterolateral portal penetrates the gluteus medius prior to entering the lateral aspect of the capsule at its anterior margin (Figure 9).

The only structure of significance relative to the anterolateral portal pathway is the superior gluteal nerve. After exiting the sciatic notch, the superior gluteal nerve courses transversely, posterior to anterior, across the deep surface of the gluteus medius. The average distance from the portal to the superior gluteal nerve is 4.4 cm.

### *Posterolateral Portal\**

The posterolateral portal penetrates both the gluteus medius and minimus prior to entering the lateral capsule at its posterior margin. Its course is superior and anterior to the piriformis tendon (Figure 10).

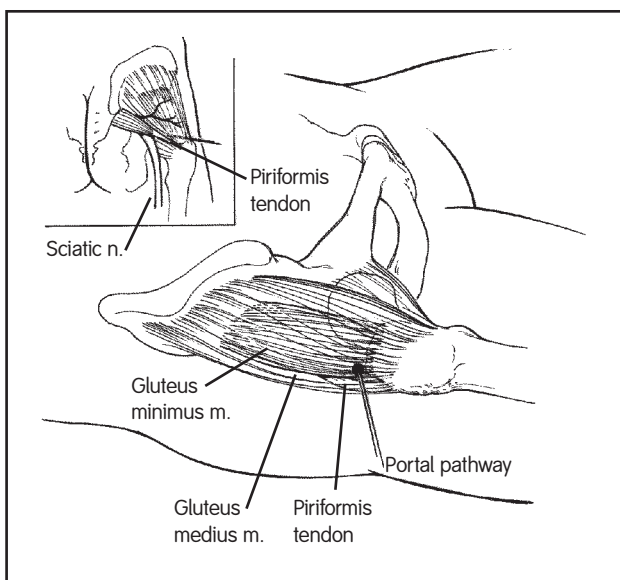


Figure 10. Posterolateral Portal Pathway/Relationship to Sciatic Nerve and Superior Gluteal Nerve

The posterolateral portal lies closest to the sciatic nerve at the level of the capsule with the distance averaging 2.9 cm. An average distance of 4.4 cm separates the portal from the superior gluteal nerve.

### *Establishing Portals*

The anterolateral portal lies most centrally in the "safe zone" for arthroscopy. Thus, it is the first portal established for introduction of the arthroscope. Subsequent portals are then placed utilizing direct arthroscopic visualization.

Pre-positioning is performed with a 6-inch, 17 gauge needle under fluoroscopic control. The hip joint is then distended with approximately 40 cc of fluid and the intra-capsular position of the needle confirmed by backflow of fluid.

A stab wound is made through the skin at the entrance site of the needle. The switching wire is placed through the needle. The needle is then removed, leaving the switching wire in place. The cannulated obturator with the 5.0 mm arthroscopy cannula is passed over the wire into the joint (Figure 11).

\* Anatomic references are based on cadaver studies and are averages only. Significant variances may exist. The surgeon must be fully familiar with the anatomy and landmarks of the region when performing hip arthroscopy.

In establishing the portal, the cannula/obturator assembly should pass close to the superior tip of the greater trochanter and then directly above the convex surface of the femoral head (Figure 12). It is important to keep the assembly off the femoral head to avoid inadvertent articular surface scuffing. However, it is also important to stay below the lateral lip of the acetabulum. If the capsule is entered more cephalad in order to avoid the femoral head, the assembly could penetrate and damage the labrum.

Once the anterolateral portal has been established, the arthroscope is inserted and initial orientation to the joint is completed. It is best to use the 70° arthroscope for placement of the other portals as it allows direct visualization of where the cannulas penetrate the capsule.

The anterior portal is the second portal created. Pre-positioning is performed with the 17 gauge spinal needle. Portal placement is facilitated by direct visualization through the arthroscope as well as fluoroscopy.

Finally, the posterolateral portal is placed. It is important to ensure that the hip has remained in neutral rotation. Specifically, if the hip is in external rotation, the greater trochanter—the main topographical landmark for portal placement—moves posteriorly. In turn, this change in trochanter location moves the portal pathway posteriorly, placing the sciatic nerve more at risk for injury (Figure 13).

As with anterolateral and anterior portal placement, pre-positioning is performed with the 17 gauge spinal needle. Fluoroscopic control and direct arthroscopic visualization are again used to ensure proper placement of the posterolateral portal.

Once all three portals have been established, one of the cannulas can be used for a separate inflow. The 5.0 mm cannula can then be replaced with a 4.5 mm cannula allowing greater ease of interchangeability of the arthroscope and instruments while assuring ample flow from the third cannula.

Releasing the capsule around the portal sites with an arthroscopic knife passed through the cannula will also improve the maneuverability of the arthroscope and instruments within the joint.

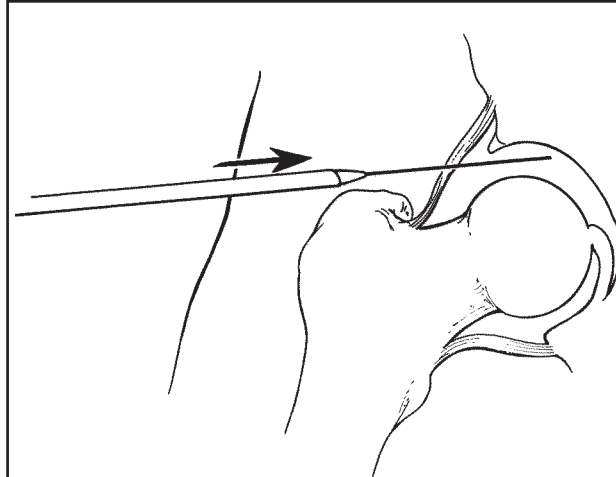


Figure 11. The switching wire guides advancement of the 5.0 mm arthroscopy cannula/cannulated obturator assembly into the joint.

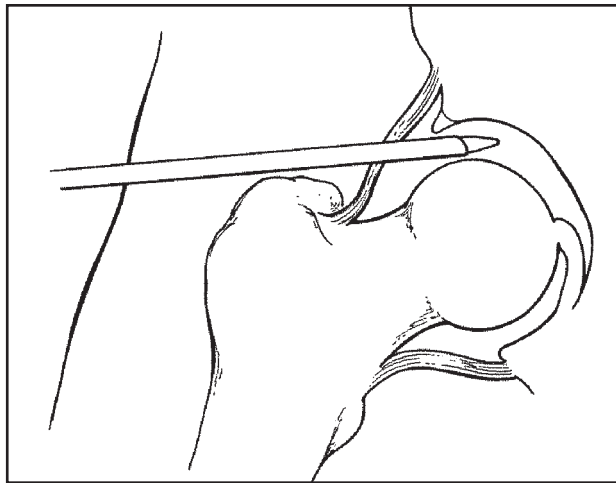


Figure 12. Advancement of the assembly via the correct anterolateral portal pathway positions cannula directly above the convex surface of the femoral head.

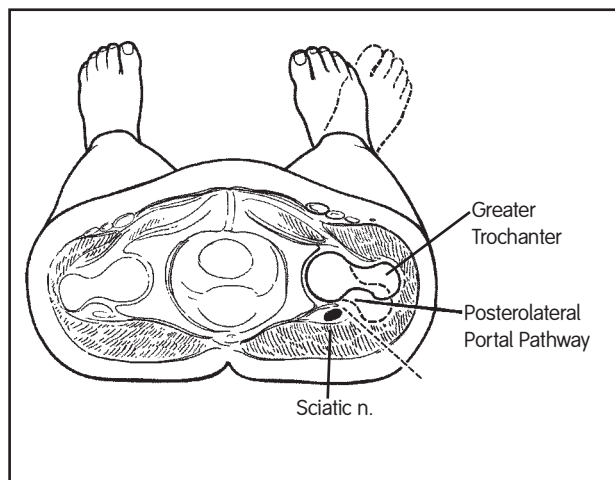


Figure 13. Neutral rotation of the operative hip is essential for protection of the sciatic nerve during placement of posterolateral portal.

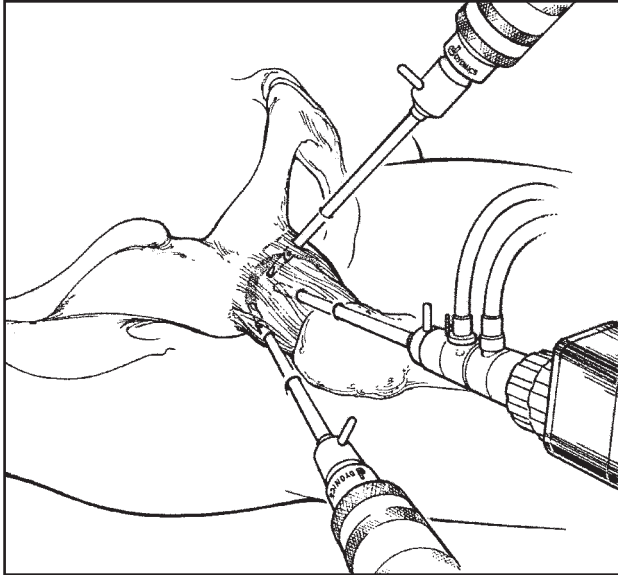


Figure 14. Established portals allow instrument and arthroscope interchange.

### Arthroscopic Examination

Systematic examination and operative arthroscopy of the hip are facilitated by interchanging the instruments and arthroscope between the three established portals (Figure 14). By utilizing both the 30° and 70° video-articulated arthroscopes, the structures that can dependably be visualized include: the superior weight bearing portion of the acetabulum; the fossa; the ligamentum teres; and the anterior, posterior and lateral aspects of the acetabular labrum. Most of the weight bearing articular portion of the femoral head can be visualized intraoperatively by internally and externally rotating the hip.

The anterior wall and anterior labrum are best visualized through the anterolateral portal (Figure 15). The posterior wall and posterior labrum are best visualized through the posterolateral portal (Figure 16). The lateral labrum and its capsular reflection are best visualized through the anterior portal (Figure 17). The fossa and ligamentum teres can usually be visualized from all three portals with a different perspective from each (Figure 18).

The inferior aspect of the acetabulum and femoral head below the ligamentum teres, the inferior capsule and the transverse acetabular ligament are occasionally able to be visualized.

At the completion of the procedure, traction is immediately released. The portals are reapproximated with nylon sutures and a sterile dressing is applied.

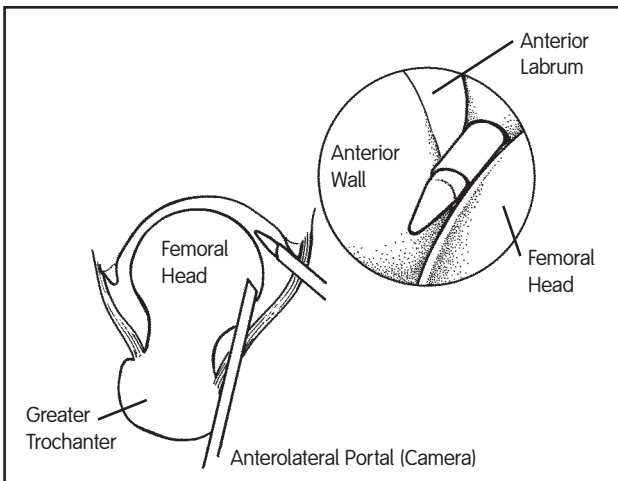


Figure 15. Anterolateral portal view.

### Postoperative Course

After hip arthroscopy, immediate ambulation is allowed. Protected weight bearing status is variable depending on the pathology addressed and procedure performed.

On the first postoperative day, the initial dressing is removed and replaced with band-aids. Sutures are removed between postoperative day three and five and replaced with steri-strips.

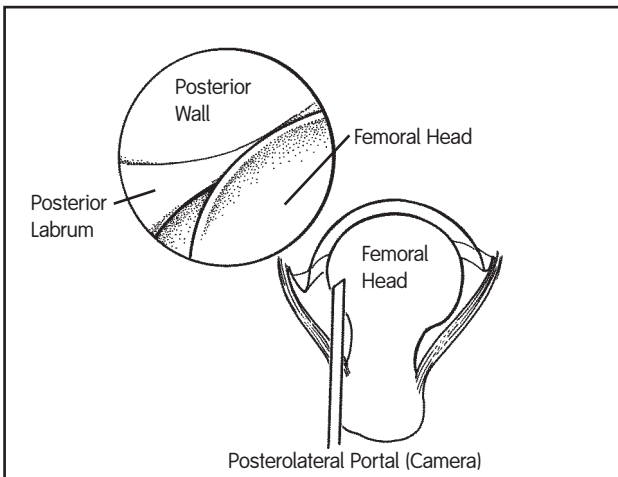


Figure 16. Posterolateral portal view.

## Rehabilitation Techniques

Rehabilitation begins with a preoperative assessment and educational program completed by a physical therapist experienced in rehabilitative techniques for patients with hip disease and those undergoing hip arthroscopy. A specific rehabilitative process is planned for each patient depending on the pathology present and the type of procedure performed.

Despite variations in pathology and procedure, the goal of the rehabilitation process, in all cases, is to return the patient to optimal function with minimal discomfort. With the exception of exclusively diagnostic arthroscopy or combined arthroscopic and open procedures, the common indication for hip arthroscopy is the alleviation of mechanical hip pain and thus the goal of rehabilitation is common as well.

Postoperatively, manual distraction mobilization techniques implemented by a skilled therapist can be very beneficial in reducing discomfort, mobilizing the hip and improving function. Importantly, range of motion is pushed only to tolerance. Unlike the shoulder or knee, limitation of motion in the hip joint is rarely a functional problem. Further, the indication for surgery is usually pain. Therefore, pushing the range of joint motion to the point of discomfort may be counterproductive.

Cocontractions and isometric exercises are begun early to initiate muscle toning. Closed chain exercises such as single leg stance may also facilitate muscle toning, proprioception and functional return while attempting to minimize the forces across the hip joint.

Functional exercises and stationary bicycle are introduced as the patient progresses and symptoms allow. The final stage of rehabilitation involves implementation of open chain exercises and isokinetic strengthening.

Given differences in functional goals and hip pathology, some patients may never reach the final stage of rehabilitation. However, for all patients, the return to optimal function with minimal discomfort remains the ultimate goal of the process.

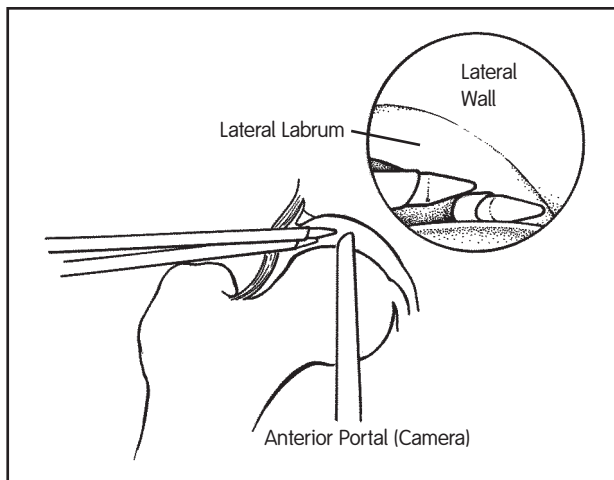


Figure 17. Anterior portal view.

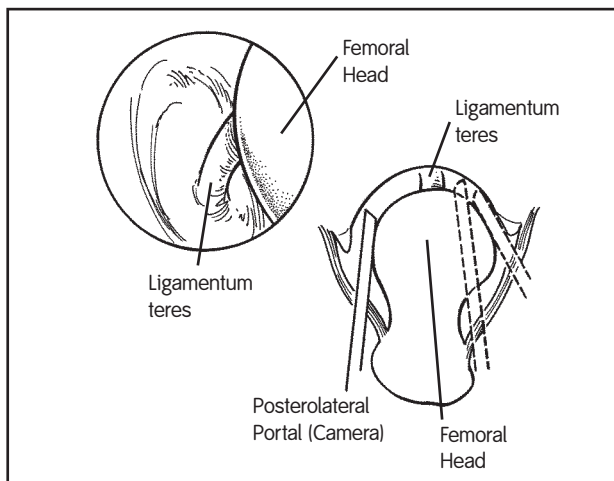


Figure 18. Visualization of the Fossa.

## Additional Instruction

Prior to performing this technique, consult the Instructions for Use provided with individual components — including indications, contraindications, warnings, cautions, and instructions.

Courtesy of Smith & Nephew, Inc.,  
Endoscopy Division

Caution: U.S. Federal law restricts this device to sale by or on the order of a physician.

\*Trademarks of Smith & Nephew. Certain marks registered U.S. Patent & Trademark Office.